



ELSEVIER



# Non-surgical correction of deformational auricular anomalies

Fabrizio Schonauer\*, Ivan La Rusca, Guido Molea

University "Federico II", Naples, Italy

Received 21 September 2007; accepted 7 November 2007

## KEYWORDS

Auricular anomalies;  
Deformed ears;  
Splintage;  
Non-surgical;  
Classification

**Summary** Less severe congenital auricular anomalies can be corrected by appropriate splinting in the early neonatal period without anaesthetic and with minimal cost. We present a series of 46 patients affected by various ear deformities (non cryptotia, non Stahl's ear, non prominent ear) that we treated by splintage during the early neonatal period. These deformational auricular anomalies were classified according to the limitation to the external ear architecture development: vertically, horizontally and focally deformed ears. This new classification guided us in splint shaping and positioning. Excellent or satisfactory results were achieved in 98% of the splinted ears. Ear splintage is an effective technique for treatment of neonates with deformational auricular anomalies.

© 2008 British Association of Plastic, Reconstructive and Aesthetic Surgeons. Published by Elsevier Ltd. All rights reserved.

Congenital ear anomalies are defined as either malformations (microtia) or deformations. Ear malformations are caused by embryologic maldevelopment that occurs between the fifth and ninth week of gestation. These malformations generally require surgical correction during childhood or adolescence.<sup>1</sup>

Ear deformations consist of a normal chondro-cutaneous component with an abnormal shape caused by deforming forces; these deformities can usually be corrected by appropriate splinting in the neonatal period.<sup>2</sup>

Constricted ear is an auricular anomaly first described by Tanzer; its definition includes anomalies such as lop ear,

cup ear, canoe ear, cockleshell ear.<sup>3</sup> More severe forms of constricted ear are characterised by varying degrees of deficiency in the skin, cartilage or a combination of both. Mild forms of constricted ear have no cartilage or skin deficits, but their shape is abnormal, especially in the upper third of the auricle. These deformities are amenable to early ear splinting.<sup>4</sup>


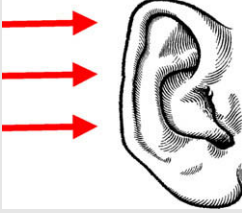
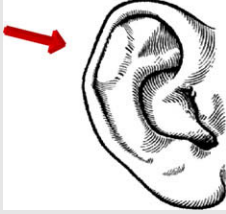
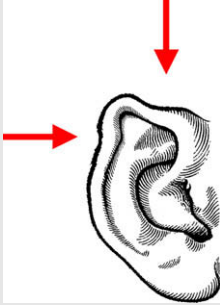
Cryptotia, Stahl's ear and prominent ear are separate clinical entities well described by many authors and are all treatable by early ear splinting.<sup>4</sup>

The residual external ear deformities amenable to splinting treatment can be grouped as *deformational auricular anomalies* and classified in three types. In this classification (Table 1) the term 'deformed' is intended as 'limitation' to the external ear shaping; in fact, intervention of internal/external forces applied on the pinna during

\* Corresponding author. Via Andrea d'Isernia 4, 80122 Naples, Italy. Tel.: +39 335436692; fax: +39 081 7463696.

E-mail address: fschona@libero.it (F. Schonauer).

**Table 1** Classification of deformational auricular anomalies

Direction of compression forces	Normal ear
Type 1: vertical compression	
Type 2: horizontal compression	
Type 3a: focal compression: inversely folded helix	
Type 3b: focal compression: multiple imprinting	

the perinatal period is one of the most accredited hypotheses to explain the aetiology of these mild deformities<sup>5</sup>:

*Type 1: vertically deformed ears*, where the pinna is mainly affected along the vertical axis (this type includes type I and II A constricted ears as classified by Tanzer<sup>3</sup>) (Figure 1);

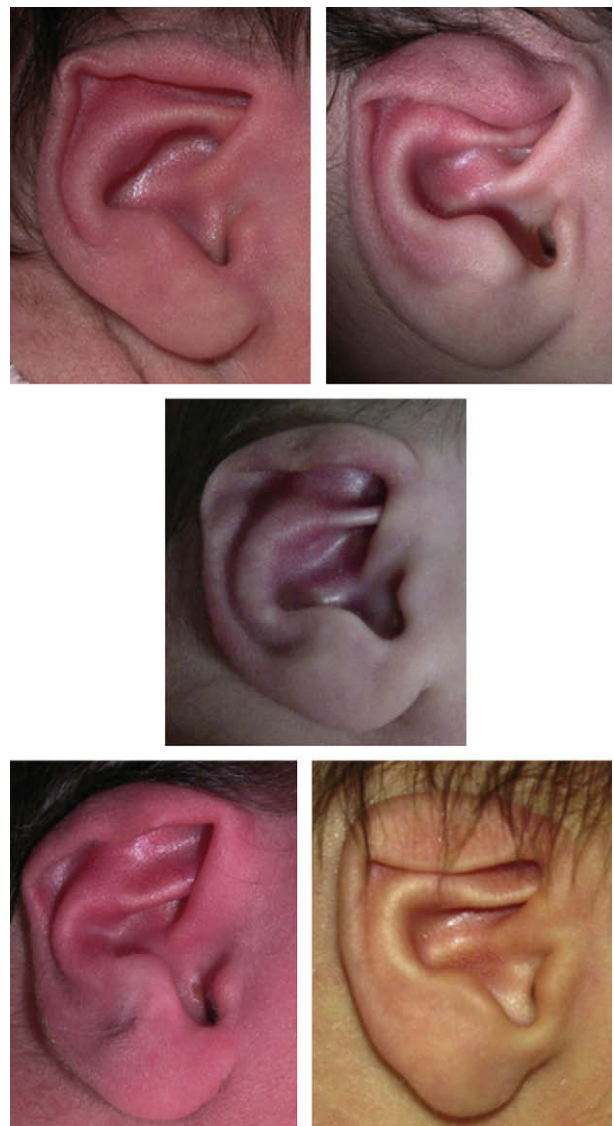
*Type 2: horizontally deformed ears*, where the limitation to the external ear development is along the horizontal axis (Figure 2);

*Type 3: focally deformed ears*, divided in two sub-types:

*Type 3a.* inversely folded helix caused by a single imprint (Figure 3)

*Type 3b.* deformity caused by multiple imprints (as kinking of the helix or pinched helix) (Figure 4)

All these deformities can be safely and effectively treated non-surgically in the early neonatal period, as first



**Figure 1** Vertically deformed ears.

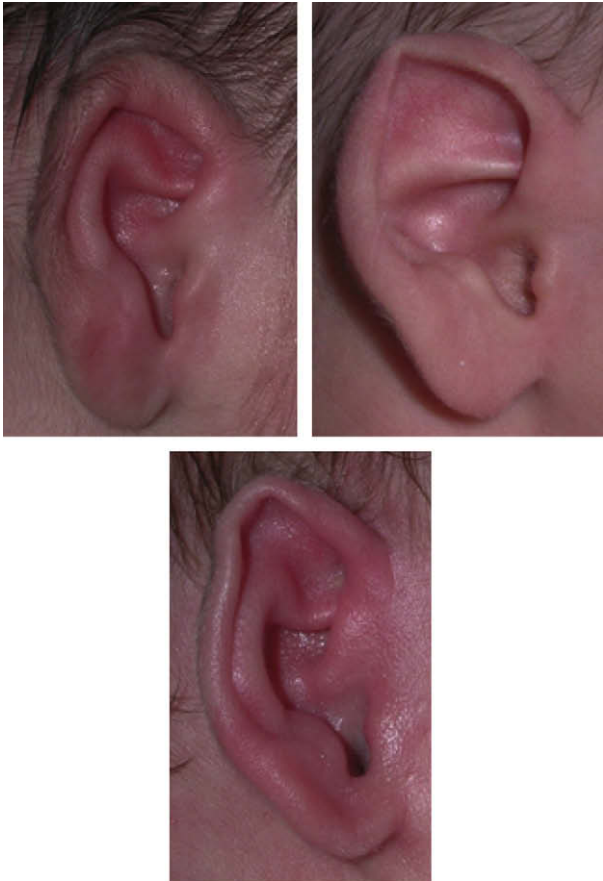

Figure 2 Horizontally deformed ears.

described by Kurozumi et al.<sup>6</sup> and Matsuo et al.,<sup>5,7</sup> using a splint to conform the external ear cartilage.

We present our experience of 46 consecutive patients with 72 deformational auricular anomalies treated over a period of 3 years.

### Materials and methods

After presenting the technique to the neonatal staff, a few newborns with different auricular deformities were referred to our Plastic Surgery Unit soon after birth (usually on day one or two after birth). Those who were found to be suitable for ear splinting were monitored. Patients with

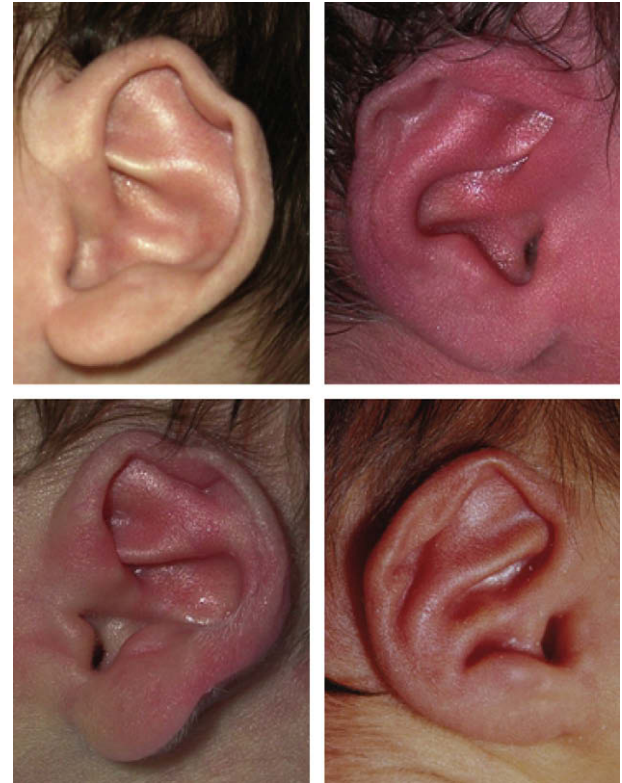


Figure 3 Focally deformed ears: inversely folded helix.

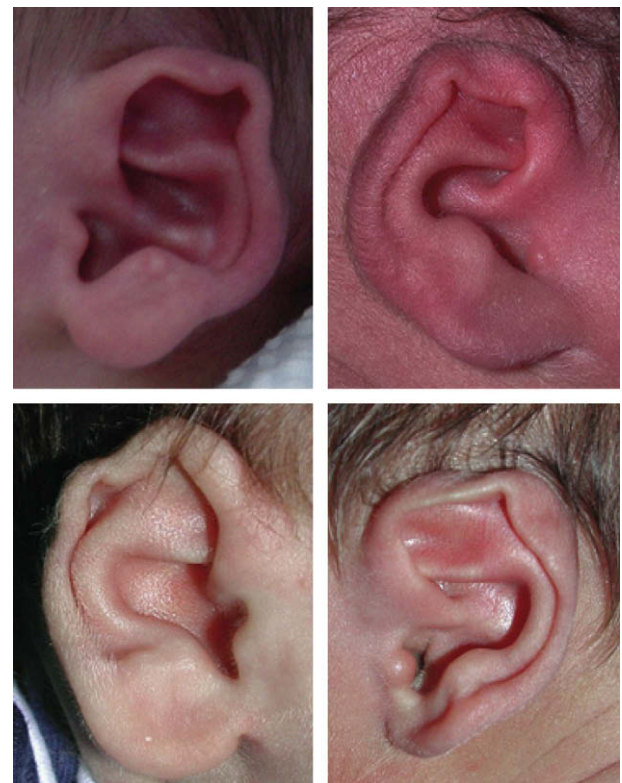


Figure 4 Focally deformed ears: multiple imprinting.

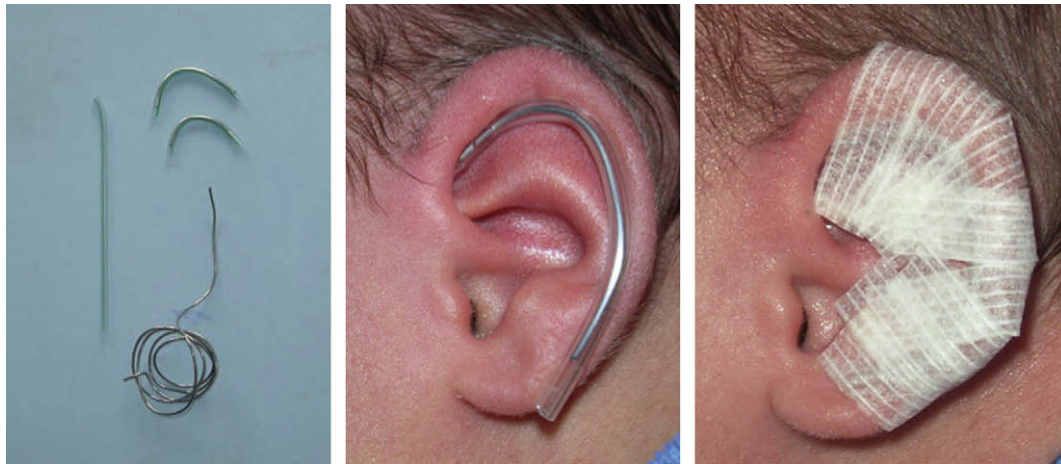

Figure 5 Ear splintage method.

Stahl's ear, prominent ears or cryptotia were treated by ear splinting as well, but they are not the subjects of this study. The natural course of the deformed auricles was observed for 48–72 h after birth to determine if spontaneous correction occurred or if splinting was indicated. Parents were then thoroughly informed about the proposed treatment, other alternatives, and the possibility of partial or total failure in achieving the desired treatment result. After that we started ear splinting as soon as possible. However, all our patients started treatment in the first 2 weeks after birth.

The method was basically the same as the one popularised in the UK by Gault et al.<sup>8</sup>

The splint was made with a wire core segment in a 6 Fr. Silastic tube. It was cut, shaped and positioned in the groove between helix and antihelix. It was held in place with three to five Steri Strips. Splintage was applied with no anaesthesia<sup>4</sup> (Figure 5).

In vertically deformed ears (type 1), interest was applied primarily in forcing the helical rim upward; the splint was

adjusted every week according to the gain obtained (Figures 6 and 7).

In horizontally deformed ears (type 2), the aim of the splintage was to 'push out and back' the auricular cartilage to recreate normal distance and proportions between the concha and helical rim (Figure 8).

In focally deformed ears with inversely folded helix (type 3a), we treated the deformity by interposition of the splint between helix and antihelix, thus recreating the groove (Figure 9).

In focally deformed ears with multiple imprints (type 3b), the splint was shaped to counter act the deformed helix in different directions as required (Figures 10 and 11).

When anterior protrusion of the scapha was associated, correction was obtained by affixing the pinna to the mastoid region with surgical tape, thereby reducing the auricular-cephalic angle. In this last condition, an elastic bandage or a headband was used for reinforcement.

The splint was applied in the clinic as an outpatient procedure with no anaesthesia; parents were asked to

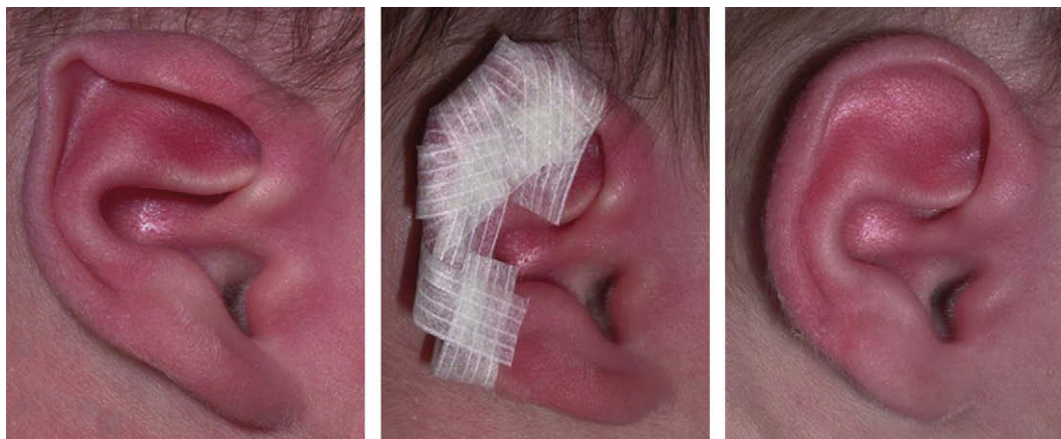
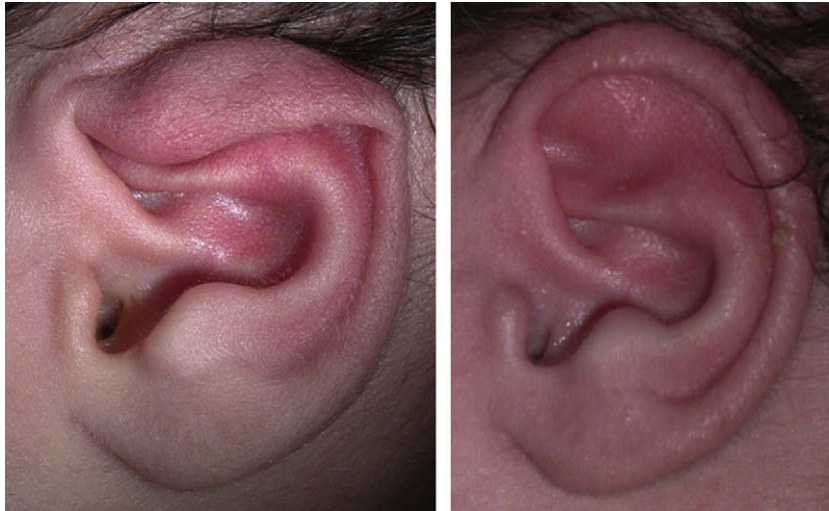


Figure 6 Type 1 – Vertically deformed ear and correction.



**Figure 7** Type 1 – Vertically deformed ear and after correction.

leave the splint in place continuously and come back with their babies at weekly intervals: in the clinic the splint was removed, the correction achieved was checked, and, if necessary, the splint was adjusted. The splint was then cleaned and reapplied with fresh steristrips. After achieving satisfactory correction, splintage was continued thereafter until correct shape was stable; that took at least one more week. In total, the period of splint application ranged between 3 and 6 weeks.

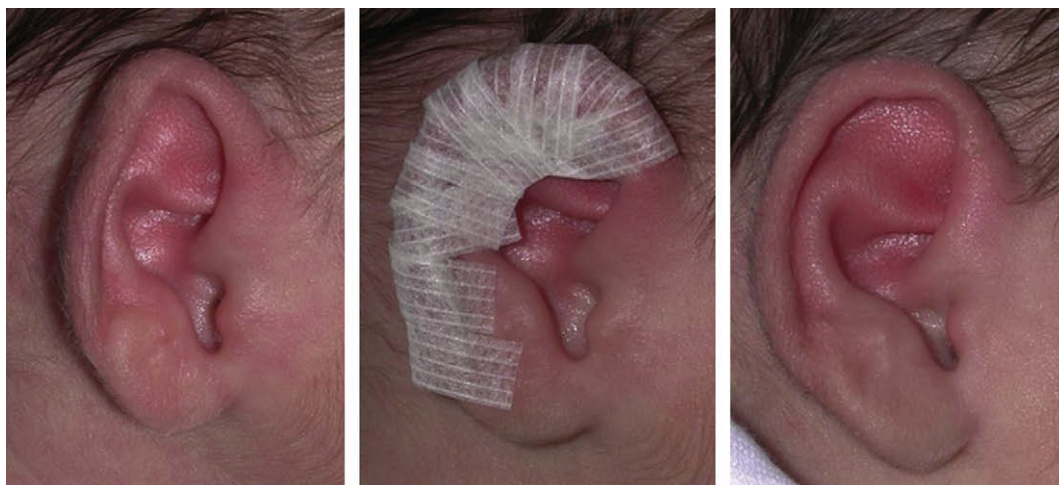
The criteria for evaluating our results fell into four categories: not improved, (not improved at all, failure of the method); improved (slight improvement that satisfied newborns' relatives but not surgeons); satisfactory (good improvement of the deformity that satisfied both newborns' relatives and surgeons); excellent (ear close to normal shape).<sup>9</sup>

## Results

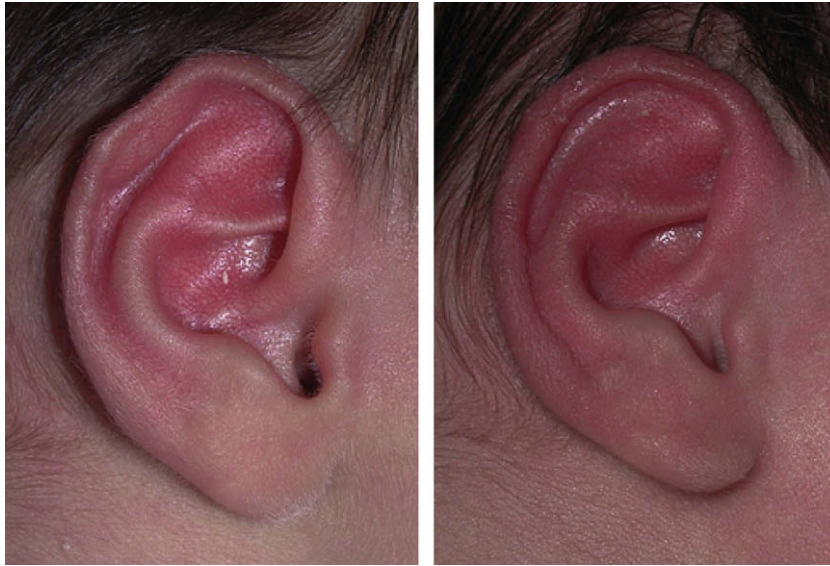
Between January 2002 and December 2004, out of a local population of 6231 newborns, 61 neonates were referred to our attention with deformed ears.

46 infants with 72 deformed ears were enrolled in our study (26 with bilateral and 20 with unilateral deformity): of these deformed ears, 37 were vertically deformed, 23 were horizontally deformed, and 12 were focally deformed (seven with multiple imprints and five with inversely folded helix). Another 15 patients were treated for Stahl's ear, prominent ear or cryptotia but are not included in this study.

Almost all the treated ears improved significantly within the first 2 weeks after the application of the splint. Horizontally deformed ears were the most difficult deformity to treat and required a longer period of splintage than



**Figure 8** Type 2 – Horizontally deformed ear and correction.



**Figure 9** Type 3a – Focally deformed ear, with inversely folded helix and its correction.

the other deformities. Superficial skin necrosis at the helical root was detected in two newborns after the first week of splint application (Figure 12); resolution of this complication was obtained spontaneously after 2 weeks in both cases; in these two patients, splintage was not abandoned.

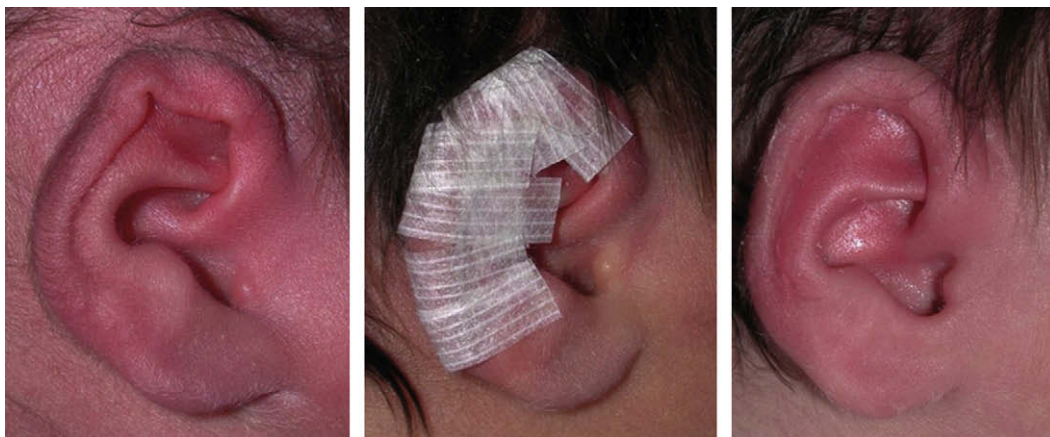Ten newborns did not complete the treatment or were lost at follow up. 36 babies with 56 deformed ears attended the clinic for review. Our follow-up ranged between 2 and 12 months. Final results were rated excellent or satisfactory in 98% of cases, while improved in 2% (Table 2).

## Discussion

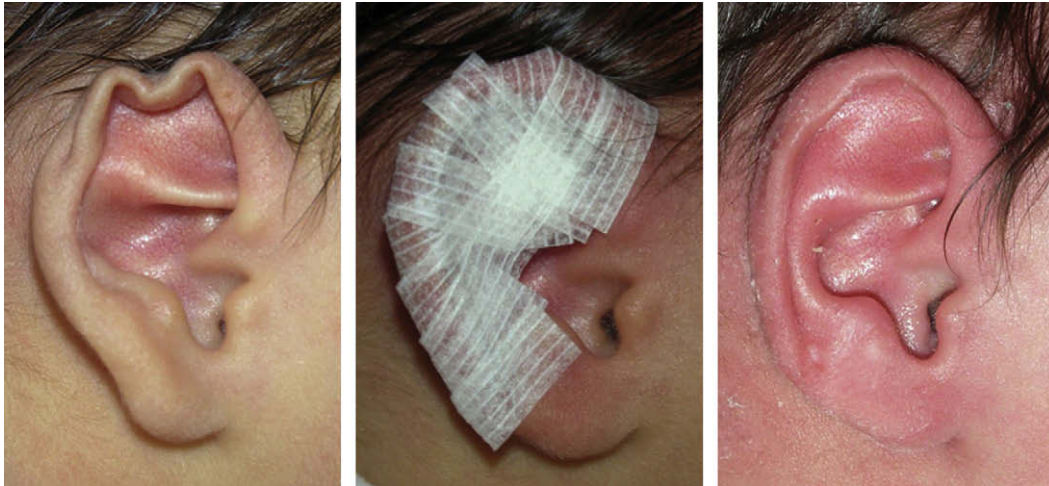
There is no consensus concerning the true incidence of abnormally shaped ears; our experience showed an incidence of 1 per 100 births (61 referrals out of 6231 newborns).

The causes of these deformities are variable and include internal/external forces applied on the auricles during the prenatal periods. The neonatal ear is soft and easily malleable. Within a few days after birth the ear becomes more elastic and firmer. This is related to the blood oestrogens levels and subsequently high levels of hyaluronic acid: circulating levels of free oestradiol are highest during the first 72 h after birth and decrease rapidly thereafter.<sup>10</sup> The ear cartilage of a newborn infant is readily mouldable and reshaping is easily achieved.<sup>11</sup> Thus, congenital ear deformities can be treated more effectively in the early neonatal period. Non-surgical correction of auricular deformities can be attempted in children older than early neonates, but reported results were good in only 50% of cases.<sup>9</sup>

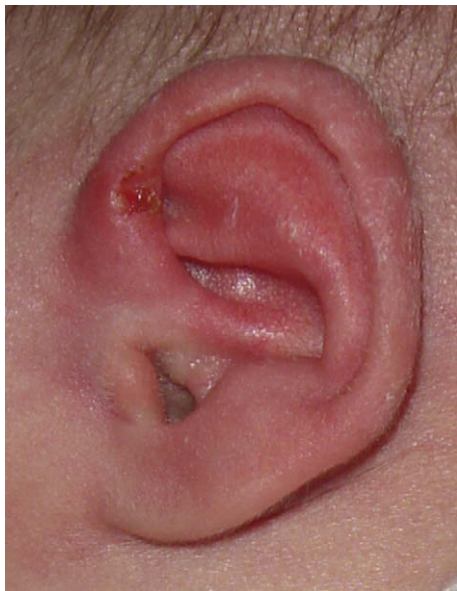After seeing a newborn with a deformational auricular anomaly that could respond to splinting, we waited 48–72 h after birth because the deformity can disappear



**Figure 10** Type 3b – Focally deformed ear, with multiple imprints and its correction.



**Figure 11** Type 3b – Focally deformed ear, with multiple imprints and its correction.



**Figure 12** Superficial skin necrosis at the helical root caused by splinting.

spontaneously.<sup>4</sup> Therefore, we do not usually apply the splint until 2–3 days after birth.

There is no agreement as to what contour irregularities constitute ‘deformities’ that should be corrected. Cosman stated that very mild forms of ear deformities

should be considered normal variants.<sup>12</sup> In our classification we include those mild forms of deformational anomalies that might bother, or not, parents of affected neonates.

The concept of vertical compression has been well explained by Tanzer<sup>3</sup> and Cosman<sup>12</sup> in their papers related to constricted ears. We accept their constricted ear classifications based on surgical approaches to different deformity degrees. Horizontal or focal compressions have never been focused on in the available English literature. A horizontally deformed ear was shown as a secondary surgery case among other constricted ear cases in a paper from Nagata.<sup>13</sup> Furnas,<sup>14</sup> in his discussion of the paper by Harlock et al.<sup>15</sup> on a series of surgically treated constricted ears, mentioned a form of horizontally deformed ear that he defined as ‘pixie’ ear. Kurozumi presented a case report in which the ear deformity is very similar to our horizontal compression.<sup>6</sup>

We are aware of Wallach and Argamaso’s description of another type of ear deformity, different from classical deformation of constricted or lop ear, named ‘crumpled ear’ deformity.<sup>16</sup> This is probably the first paper in which the effects of ‘pressing, bending or crushing out of shape’ the external ear were focused and differentiated by other, previously classified, ear deformities. Porter and Tan<sup>1</sup> showed a deformation of the ear helix defined as ‘crinkled ear’ that looked like our focal compression with multiple imprinting (type 3b).

**Table 2** Clinical results

Deformational auricular anomalies	Improved	Satisfactory	Excellent	Total
Type 1: vertically deformed		3	25	28
Type 2: horizontally deformed	1	4	13	18
Type 3a: inversely folded helix		1	3	4
Type 3b: multiple imprints		1	5	6
Total	1	9	46	56
Result	2%	16%	82%	

We propose this new classification (Table 1) based on the assumption that the deformities included in the scheme can all be treated with the same non-surgical method, directed at unfolding the deformed cartilage. In it we put together different types of mild to moderate deformational anomalies sharing a form of compression. Furthermore, recognising the direction of the primary compression suggests how the splint should be conformed and applied; in fact, it needs to act as a counterbalance to the original compression.

Our neonates returned to the clinic for weekly follow-ups until the deformity was corrected and the ear shape stable, which usually took from 3 to 4 weeks. We believe that splinting is not a procedure that can be carried out by parents themselves. In fact, each splint should be progressively adjusted according to the evolution of the correction.

We conclude that ear splintage is a simple and effective procedure that should be offered more frequently to parents of affected neonates. Our study confirmed that very early correction can avoid both an anaesthetic and the need for later surgical correction.

## References

- Porter CJ, Tan ST. Congenital auricular anomalies: topographic anatomy, embryology, classification, and treatment strategies. *Plast Reconstr Surg* 2005;115:1701–12.
- Brown FE, Colen LB, Addante RR, et al. Correction of congenital auricular deformities by splinting in the neonatal period. *Pediatrics* 1986;78:406–11.
- Tanzer RC. The constricted (cup and lop) ear. *Plast Reconstr Surg* 1975;55:406.
- Schonauer F, Fera G, La Rusca I, et al. Splintage for correction of congenital ear deformities. *Eur J Plast Surg* 2003;26:290–3.
- Matsuo K, Hayashi R, Kiyono M, et al. Nonsurgical correction of congenital auricular deformities. *Clin Plast Surg* 1990;17:383–95.
- Kurozumi N, Ono S, Ishida H. Non surgical correction of a congenital lop ear deformity by splinting with Reston foam. *Br J Plast Surg* 1982;35:181.
- Matsuo K, Hirose T, Tomono T, et al. Nonsurgical correction of congenital auricular deformities in the early neonate: a preliminary report. *Plast Reconstr Surg* 1984;73:38.
- Tan ST, Shibu M, Gault DT. A splint for correction of congenital ear deformities. *Br J Plast Surg* 1994;47:575–8.
- Yotsuyanagi T, Yokoi K, Urushidate S, et al. Nonsurgical correction of congenital auricular deformities in children older than early neonates. *Plast Reconstr Surg* 1998;101:907–14.
- Kenny FM, Angsusingha K, Stinson D, et al. Unconjugated estrogens in the perinatal period. *Pediatr Res* 1973;7:826–31.
- Lindford AJ, Hettiaratchy S, Schonauer F. Postpartum splinting of ear deformities. *BMJ* 2007;334:366–8.
- Cosman B. The constricted ear. *Clin Plast Surg* 1978;5:389–400.
- Nagata S. Alternative surgical methods of treatment for the constricted ear. *Clin Plast Surg* 2002;29:301–15.
- Furnas DW. 5-Year series of constricted (lop and cup) ear corrections: development of the mastoid hitch as an adjunctive technique. *Plast Reconstr Surg* 1998;102:2333–5 [discussion].
- Horlock N, Grobbelaar AO, Gault DT. 5-year series of constricted (lop and cup) ear corrections: development of the mastoid hitch as an adjunctive technique. *Plast Reconstr Surg* 1998;102:2325–32.
- Wallach SG, Argamaso RV. The crumpled-ear deformity. *Plast Reconstr Surg* 2001;108:30–7.