



ELSEVIER



CASE REPORT

Digital nerve reconstruction by multiple Y-shaped nerve grafts at the metacarpophalangeal joint level

Fabrizio Schonauer*, Salvatore Tagliatela Scafati,
Ivan La Rusca, Guido Molea

Department of Plastic and Reconstructive Surgery, University of Naples "Federico II", Italy

Received 6 January 2008; accepted 3 April 2008

KEYWORDS

Digital nerve;
Nerve graft;
Donor site;
Y-shaped;
Hand injury

Summary Digital nerve injuries are common; injuries of the common digital nerves are less frequent than those involving the proper digital nerves.

Traditional techniques used to reconstruct peripheral nerves are: direct suture, autologous nerve grafts, autologous vein grafts, vascularised nerve graft and alloplastic nerve grafts. Autologous nerve grafts remain the most common conduits for segmental defects.

Difficulties can arise when attempting to repair complex nerve gaps, particularly when joining the proximal stump of the common digital nerve with two distal stumps of proper digital nerves as in lesions involving the web space. We present below a case of such a lesion.

We describe the use of the lateral antebrachial cutaneous nerve (LABCN) as donor nerve, by exploiting its natural branchings.

© 2008 Published by Elsevier Ltd on behalf of British Association of Plastic, Reconstructive and Aesthetic Surgeons.

Case report

A 23-year-old right-handed man presented to the A&E department after sustaining a circular saw injury at the level of the distal palmar crease of the right hand, with severe soft tissue damage. Clinical assessment revealed a flexor tendon injury to the index and middle finger. Sensation was absent from both the ulnar and radial aspect of the 2nd, 3rd, 4th and 5th fingers. Complete division of

flexor digitorum superficialis (FDS) and flexor digitorum profundus (FDP) of the 2nd and 3rd finger along with complete division of eight digital nerves of the finger from the 2nd to the 5th were detected.

Exploration was carried out, under general anaesthetic, by extended zig-zag incisions. Flexor tendons of both the index and middle fingers were exposed and repaired using the modified Kessler technique using 3/0 Ethibond core and 5/0 Ethilon epitendinous sutures.

The ulnar proper digital nerve of the fifth finger and the radial proper digital nerve of the second finger were repaired without tension by end-to-end approximation using 9/0 Ethilon epineural sutures.

* Corresponding author. Address: Via Andrea D'Isernia 4, 80122 Naples, Italy. Tel.: +39 335436692.

E-mail address: fschona@libero.it (F. Schonauer).

The common digital nerves of the 2nd, 3rd and 4th web spaces appeared to be 100% divided at the level of their bifurcation. After debridement, nerve gaps of the three web spaces needed graft reconstruction (Figure 1).¹ A homolateral lateral antebrachial cutaneous nerve (LABCN) graft was then harvested, including two bifurcations at different levels (Figure 2). The nerve graft was divided into four segments: two linear segments were used as a V-shaped graft to recreate the natural bifurcated configuration of the common digital nerve at the second web space. The proximal stump of each segment was sutured to the proximal stump of the 2nd common digital nerve. Their distal stumps were separately sutured to the distal stumps of the ulnar proper digital nerve of the second finger and the radial proper digital nerve of the third finger. Further, two nerve graft segments, Y-shaped, were used to bridge the nerve gaps in the third and fourth web spaces. Ethilon epineural sutures (9/0) were used under microscope magnification. The proximal stump of each Y-shaped graft was sutured to the stump of the common digital nerve at the level of the third and fourth web spaces while the distal stumps of the Y-grafts were sutured to their respective proper digital nerve (Figures 3 and 4).

The wound was closed using 5/0 Ethilon sutures. Tetanus prophylaxis and metronidazole and penicillin G antibiotics were administered; the hand was elevated and splinted.

Results

No intraoperative complications were recorded. A rehabilitation scheme was followed for 10 weeks.

At the 12-month follow up, a full range of movement was obtained.

Evaluation of function was based on the Medical Research Council (MRC) classification for sensory recovery.² The two-point discrimination (2PD) test with a Disk-criminator was performed: sensation recovery was good for all fingers and classified as S3+ (Figure 5).

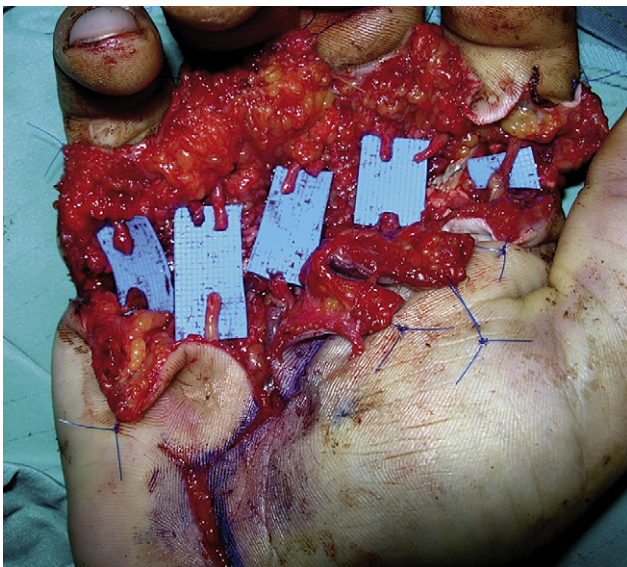

Figure 1 Multiple nerve defects after debridement.

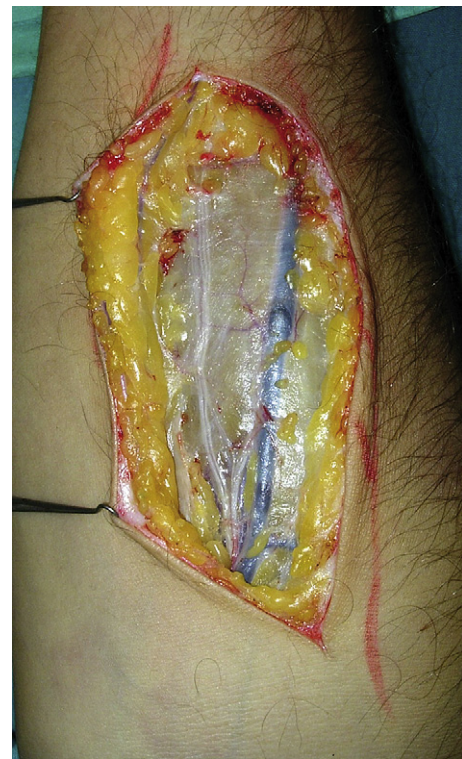

Figure 2 LABCN harvesting.

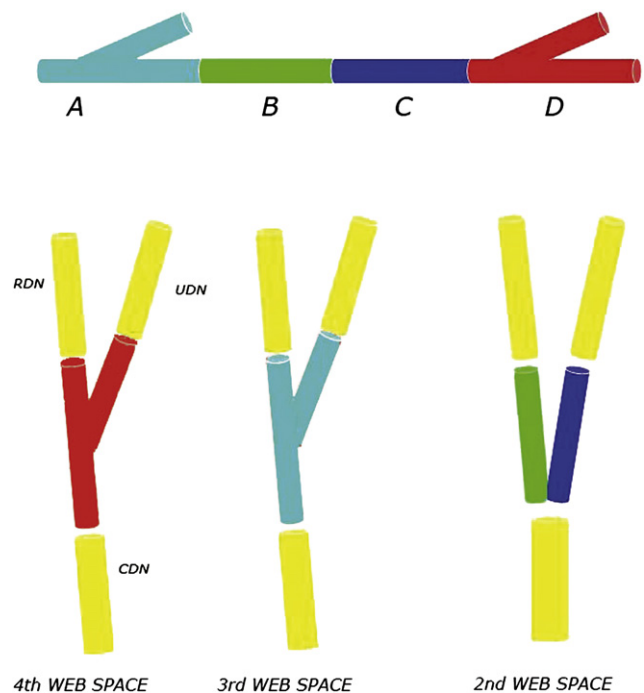


Figure 3 Scheme of LABCN graft preparation: section A includes the proximal bifurcation, section B and C share the same linear pattern and section D includes the distal bifurcation. CDN, common digital nerve; RDN, radial digital nerve; UDN, ulnar digital nerve.

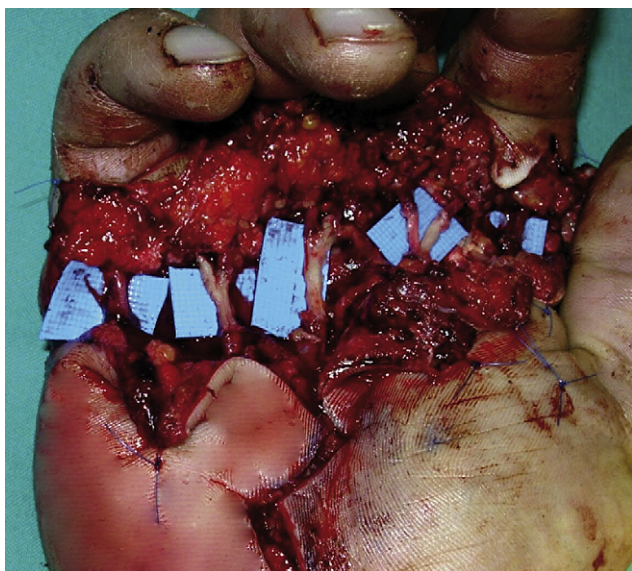


Figure 4 Reconstruction of bifurcations of the common digital nerves.

Discussion

In this case we needed to recreate the Y-shaped configuration of three common digital nerves lying at the web space level: we used two Y-shaped nerve grafts and one paired V-shaped nerve graft.

Y-shaped grafts have been described in the literature as a way to reconstruct the normal anatomy of several structures. In 1991 Stevanovic³ reported that, in avulsion injuries involving the thumb, the survival rate of the replanted digits

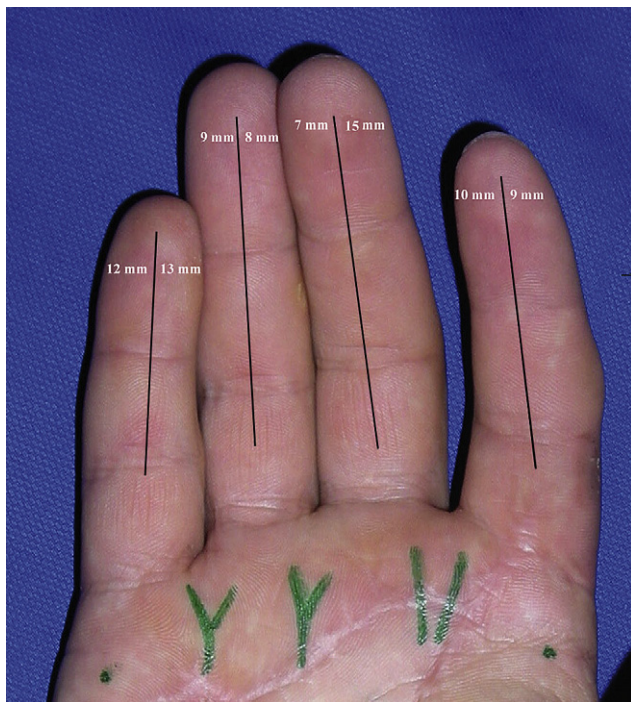


Figure 5 Twelve-month follow up with two-point discrimination test values.

was improved by using Y-shaped vein grafts as a source of arterial circulation to restore continuity between two digital arteries and the princeps pollicis artery.

In 1992, Zhao⁴ employed Y-shaped silicone tubes for nerve regeneration in the rat tibial/peroneal nerve experimental model, obtaining recovery of about 90% of the tetanic force after electric stimulation.

Tos⁵ used muscle-vein-combined Y-shaped conduits in the median/ulnar rat model achieving a good nervous recovery.

The use of Y-shaped nerve grafts in digital nerve reconstruction has previously been reported only by Tenny and Lewis⁶ who, in a series of 40 consecutive patients suffering from hand injuries, described three cases in which Y-grafts were used to bridge the common digital nerve to the proper digital nerves.

When compared to the classical use of paired V-shaped nerve grafts, Y-shaped nerve grafts have two major advantages: they minimise the presence of suture material at the proximal anastomotic site and allow the regenerated nerve fibres to grow along the Y-shaped structure of the graft.

Donor selection for nerve graft depends on the ease of harvesting and on post surgical morbidity.

Donor nerves for peripheral nerve reconstruction include: the sural nerve, medial antebrachial cutaneous nerve (MABCN) and LABCN of the forearm, the superficial branch of the radial nerve and terminal sensitive branches of the posterior interosseous nerve.

The MABCN can provide up to a 10 cm graft. The resultant sensory deficit lies along the medial aspect of the mid-forearm.⁷ The MABCN has also been reported as a donor graft for repair of facial nerve defects.⁸

Higgins⁹ provided criteria for the selection of donor sites for nerve harvest in digital nerve reconstruction. He investigated the cross-sectional area and number of fascicles of both donor nerves and specific digital nerve segments. The LABCN proved to be the more suitable graft for defects at the common digital nerve bifurcation level. The LABCN is the terminal branch of the musculocutaneous nerve and provides sensory innervation to the volar forearm. It is easily harvested medial to the cephalic vein, below the elbow. Both anterior and posterior divisions can be obtained, giving approximately 12 cm of nerve graft.¹⁰

In terms of morbidity, harvested LABCN sensory deficit, in the radial aspect of the volar forearm, can be considered negligible due to the overlap in distribution by the radial sensory branch.¹¹

In conclusion, when harvested with its branches at the proximal forearm, LABCN is the most valuable solution to provide Y-shaped nerve grafts.

References

1. Noble J, Munro CA, Prasad VS, et al. Analysis of upper and lower extremity peripheral nerve injuries in a population of patients with multiple injuries. *J Trauma* 1998;**45**:116–22.
2. *Peripheral nerve injuries*. HMSO; 1954. p. 354–361.
3. Stevanovic MV, Vucetic C, Bumbasirevic M, et al. Avulsion injuries of the thumb. *Plast Reconstr Surg* 1991;**87**:1099–104.
4. Zhao Q, Dahlin LB, Kanje M. Reinnervation of muscles in rats after repair of transected sciatic nerves with Y-shaped and

- X-shaped silicone tubes. Muscle reinnervation after nerve repair. *Scand J Plast Reconstr Surg Hand Surg* 1992;26:265–70.
5. Tos P, Calcagni M, Gigo-Benato D, et al. Use of muscle-vein-combined Y-chambers for repair of multiple nerve lesions: experimental results. *Microsurgery* 2004;24:459–64.
 6. Tenny JR, Lewis RC. Digital nerve grafting for traumatic defects. Use of the lateral antebrachial cutaneous nerve. *J Bone Joint Surg [Am]* 1984;66:1375–9.
 7. Nunley JA, Ugino MR, Goldner RD, et al. Use of the anterior branch of the medial antebrachial cutaneous nerve as a graft for the repair of defects of the digital nerve. *J Bone Joint Surg [Am]* 1989;71:563–7.
 8. Haller JR, Shelton C. Medial antebrachial cutaneous nerve: a new donor graft for repair of facial nerve defects at the skull base. *Laryngoscope* 1997;107:1048–52.
 9. Higgins JP, Fisher S, Serletti JM, et al. Assessment of nerve graft donor sites used for reconstruction of traumatic digital nerve defects. *J Hand Surg [Am]* 2002;27:286–92.
 10. Matsuyama T, Mackay M, Midha R. Peripheral nerve repair and grafting techniques: a review. *Neurol Med Chir [Tokyo]* 2000;40:187–99.
 11. Brandt KE, Mackinnon SE. Microsurgical repair of peripheral nerves and nerve graft. In: *Grabb and Smith's plastic surgery*. 5th ed. Philadelphia: Lippincott Raven; 1997. p. 88.